



Management of Primary HLH

ABBREVIATIONS

EBV	Epstein-Barr virus
HLA	Human leucocyte antigen
HLH	Haemophagocytic lymphohistiocytosis
HSC	Haematopoietic stem cell
HSCT	Haematopoietic stem cell transplantation
IEI	Inborn errors of immunity
IPOPI	International Patient Organisation for Primary Immunodeficiencies
PID	Primary immunodeficiency

Haemophagocytic lymphohistiocytosis (1st edition)

© International Patient Organisation for Primary Immunodeficiencies (IPOPI), 2024

Published by IPOPI: **IPOPI.org**

SUMMARY

Haemophagocytic lymphohistiocytosis (HLH) is a rare immune disorder where the body reacts incorrectly to a 'trigger', usually an infection, or malignancy. Specialised white blood cells (T-cells and macrophages) become over-activated, causing severe inflammation and damage to tissues such as the liver, spleen, lungs, skin, brain and bone marrow. Primary (or familial) HLH is caused by an inherited genetic mutation and is usually fatal typically within a few months if not detected and treated.

Initial clinical symptoms are typically a high and unremitting temperature, skin rash, swollen liver and spleen, jaundice, enlarged lymph nodes (lymphadenopathy) and low counts of all types of blood cells (pancytopenia). There may also be anaemia, opportunistic infections, bruising, bleeding and, if the brain is affected, symptoms such as seizures, ataxia (imbalance) or drowsiness may occur. Skin manifestations can include widespread reddening of the skin because of inflammation (erythroderma), rashes, blood spots (purpura) and tiny spots on the skin (petechiae) that often occur on the scalp and behind the ears.

As HLH is an emergency scenario, it is important to start therapy as soon as possible and this is often before confirmation of genetic diagnosis of the disease. Initial treatments for HLH include aggressive courses of immunosuppressants and anti-inflammatory agents, such as glucocorticosteroids. Regimens that include combinations of these classes of drugs can diminish and slow the effects of the disease, but relapse is to be expected in patients who have primary HLH and antibiotics, antiviral and antifungal drugs, together with immunoglobulin replacement therapy, are often administered to combat opportunistic infections. Curative treatment for primary/familial HLH involves hematopoietic stem cell transplantation (HSCT). The earlier a proper diagnosis is made, the earlier a transplant can be performed and the better its chances of success.

INTRODUCTION

This booklet explains what HLH is, its manifestations, how it is diagnosed, treated and managed.

Haemophagocytic lymphohistiocytosis (HLH) is a rare immune disorder where the body reacts incorrectly to a 'trigger', usually an infection. Specialised white blood cells (known as T-cells and macrophages) become over-activated, causing severe inflammation and damage to tissues such as the liver, spleen, lungs, skin and bone marrow. Primary (familial) HLH is an inherited form of HLH, while secondary (acquired) HLH occurs after strong immunological activation, such as that occurring with systemic infection, immunodeficiency, or underlying malignancy. If not detected and treated, primary HLH is usually fatal, typically within a few months.

The incidence of primary (familial) HLH is reported to be 1.2 cases per million persons per year. However, unpublished observations estimate that these figures have slightly increased over time because of improved detection; this amounts to 1 case per every 50,000 births.¹ The disease has an equal distribution among males and females and appears to be unaffected by race. The age of onset of primary HLH is usually in persons younger than 1 year of age (although it can be older, including in young adults on some occasions) while for the secondary form it is usually after 6 years of age.²

Primary HLH is a rare disease and can be difficult to diagnose because many of the symptoms can mimic severe infection or other conditions. In addition to over-activation of white blood cells, various primary immunodeficiencies (PIDs), which are now also referred to as inborn errors of immunity (IEI), have been identified among patients suffering from HLH.

WHAT CAUSES HLH?

Primary (familial) HLH is caused by a genetic mutation, so it can be inherited from the parents either as an X-linked (sex-linked) recessive defect where the gene is inherited from the mother, or as an autosomal recessive defect where both parents carry a defective gene. Family history can be helpful in establishing the possible role of genes or chromosomes in HLH and in identifying a pattern of inheritance.

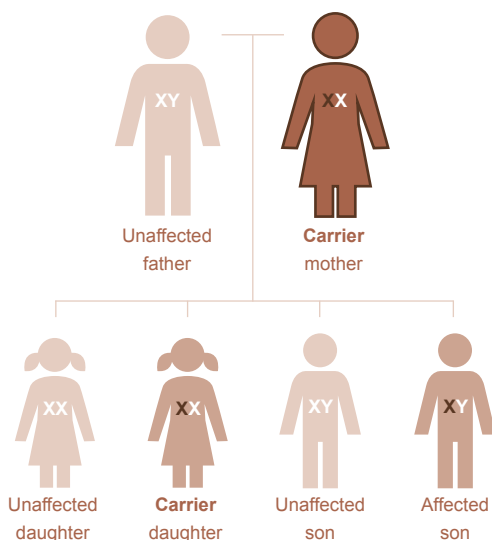


FIGURE 1. Inheritance pattern of X-linked HLH with a carrier mother

For X-linked recessive HLH, the gene causing disease is present on the X chromosome. Males have only one X chromosome that is inherited from their mother, so if a male inherits an X chromosome that contains a defective gene, he will develop the disease (**Figure 1**). Females have two X chromosomes, so those that have a defective gene present on one of their X chromosomes are “carriers” for that disorder (**Figure 1**).

As can be seen from Figure 1, women who are carriers of an X-linked disorder, such as HLH, have a 25% chance with each pregnancy of having a carrier daughter like themselves, a 25% chance of having a non-carrier daughter, a 25% chance of having a son affected with the disease and a 25% chance of having an unaffected son (**Figure 1**).

A man with X-linked HLH will pass the defective gene to all of his daughters, who will be carriers, while none of his sons will be affected as he cannot pass an X-linked gene to his sons because males always pass their Y chromosome to male offspring (**Figure 2**).

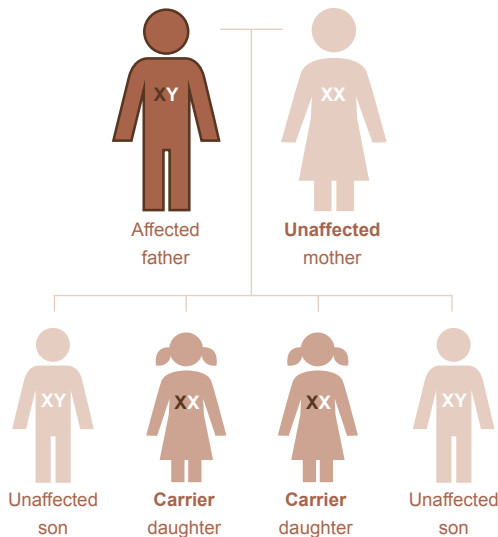


FIGURE 2. Inheritance pattern of X-linked HLH with an affected father

¹ Sung L, King SM, Carcao M, et al. Adverse outcomes in primary hemophagocytic lymphohistiocytosis. *J Pediatr Hematol Oncol* 2002; 24: 550–554.

² Imashuku S, Ueda I, Teramura T, et al. Occurrence of haemophagocytic lymphohistiocytosis at less than 1 year of age: analysis of 96 patients. *Eur J Pediatr* 2005; 164: 315–319.

For autosomal recessive inheritance, two abnormal copies of the gene, typically one from each parent, must be inherited to cause symptoms of the condition. Usually, parents of the affected child each carry one copy of an abnormal gene and are unaffected themselves because of the normal functioning of the other gene. If both parents are carriers of an abnormal autosomal recessive gene, this leads to a 25% chance (1 in 4) that any offspring, irrespective of gender, will be affected by the disorder. There is a 50% chance (1 in 2) that the offspring will be a carrier (have one abnormal gene), and a 25% (1 in 4) that the baby will not inherit the faulty gene from either parent, and therefore will not be affected by the condition or be able to pass it on to their children (**Figure 3**). The chances remain the same for all future pregnancies, and the outcome of each pregnancy is not affected by previous pregnancies.

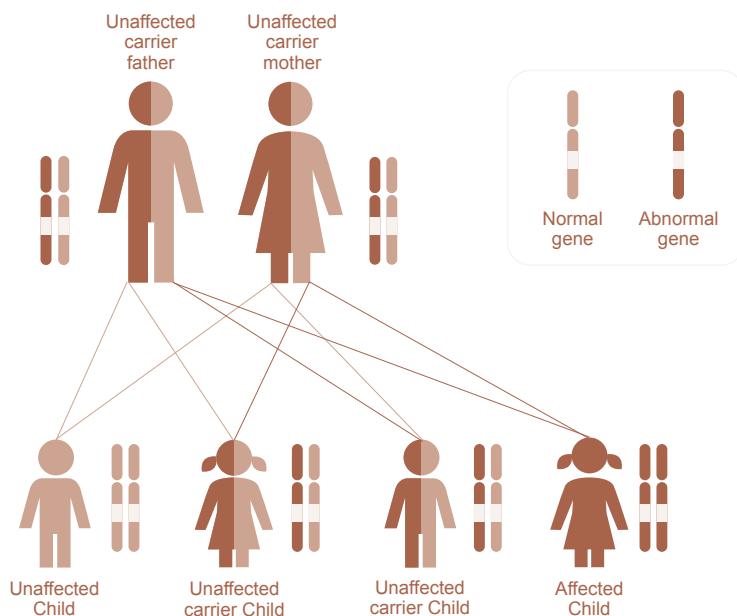


FIGURE 3. Inheritance pattern of autosomal recessive HLH with a carrier mother and a carrier father

Primary HLH is caused by variants in several genes, including *PRF1*, *UNC13D*, *STXBP2*, *STX11*, *RAB27A*, *LYST*, *AP3B1*, *SH2D1A* and *XIAP/BIRC4*.³ When patients have variants in *SH2D1A* or *XIAP/BIRC4*, they are usually classified as having X-linked lymphoproliferative disease type 1 or 2, respectively (XLP1 and XLP2). When patients have mutations in *RAB27A*, they have Griscelli syndrome type 2. Patients who have mutations in *LYST* have Chediak-Higashi syndrome. There are other related disorder genes, such as *NLR4*, that can also cause HLH.

SIGNS AND SYMPTOMS – CLINICAL PRESENTATION OF HLH

The symptoms of HLH can be confused with common childhood illnesses but are more severe. Initial clinical features are typically a high and unremitting temperature, skin rash, swollen liver and spleen, jaundice, enlarged lymph nodes (lymphadenopathy) and low counts of all types of blood cells (pancytopenia). There may be anaemia, opportunistic infections or excessive bruising and bleeding. If the brain is affected, symptoms such as seizures, ataxia (wobbliness), drowsiness or even coma may also occur although central nervous system involvement might remain clinically quiet and underdiagnosed, but it can also be affected. Additional symptoms can include problems breathing (lung dysfunction), severe low blood pressure (hypotension), liver inflammation (hepatitis), and abdominal swelling due to fluid accumulation (ascites).

The skin is involved in up to 65% of patients with primary HLH, with manifestations that can include widespread reddening of the skin because of inflammation (erythroderma), rashes, blood spots (purpura) and tiny spots on the skin (petechiae) that often occur on the scalp and behind the ears.⁴ Detection of skin involvement can assist in the initial diagnosis of HLH and can potentially signify recurrences. HLH can also be a marker for underlying cancer, which, if occurring in adults, is most often a lymphoma that may be rapidly progressive.⁵ Other findings include swollen or haemorrhagic gums that can lead to tooth loss, feeding problems (which can be especially prominent in infants), abdominal pain, vomiting, diarrhoea and weight loss.

³ Gholam C, Grigoriadou S, Gilmour KC, et al. Familial haemophagocytic lymphohistiocytosis: advances in the genetic basis, diagnosis and management. *Clin Exp Immunol* 2011; 163: 271–283.

⁴ Morrell DS, Pepping MA, Scott JP, et al. Cutaneous manifestations of hemophagocytic lymphohistiocytosis. *Arch Dermatol* 2002; 138: 1208–1212.

⁵ Pasvolosky O, Zoref-Lorenz A, Abadi U, et al. Hemophagocytic lymphohistiocytosis as a harbinger of aggressive lymphoma: a case series. *Int J Hematol* 2019; 109: 553–562.



DIAGNOSIS OF HLH

When most of the typical clinical signs are present and HLH is suspected, blood tests can help confirm the diagnosis by measuring the levels of the different blood cell types, as well as various markers that indicate excessive immune activity. The Histiocyte Society have set forth fulfilling five of the following eight criteria to establish a diagnosis of HLH:⁶

Clinical criteria

- Fever – ≥ 7 days of a temperature as high as 38.5°C (101.3°F)
- Splenomegaly – A palpable spleen greater than 3 cm below the costal margin

Laboratory criteria

- Pancytopenia – Counts below the specified range in at least two of the following cell types:

o absolute neutrophil count $< 1,000/\mu\text{L}$

o platelet count $< 100,000/\mu\text{L}$

o haemoglobin level $< 9.0 \text{ g/dL}$

- Hypofibrinogenaemia ($< 1.5 \text{ g/L}$) and/or hypertriglyceridaemia ($> 3.0 \text{ mmol/L}$)
- Ferritin $\geq 500 \text{ ng/mL}$
- Soluble IL2 receptor (CD25) $\geq 2400 \text{ IU/mL}$ or 2 standard deviations above reference value
- Low or absent natural killer (NK) cell activity

Histological criteria

- Haemophagocytosis

Because natural killer cell function or activity is decreased in up to 90% of patients with HLH, it is one of the most useful laboratory tests, but natural killer cell number is not diagnostic.

A skin biopsy can assist in ruling out other systemic and potentially neoplastic diseases; however, the findings are usually not diagnostic and only rarely show HLH. A bone marrow aspirate can be extracted to look for evidence of HLH, and a lumbar puncture (spinal tap) may also be performed to look for increased protein levels in the spinal fluid. If these tests are positive, genetic testing can be used to test for variants in genes known to be involved in primary HLH.

⁶ Buyse S, Teixeira L, Galicier L, et al. Critical care management of patients with hemophagocytic lymphohistiocytosis. *Intensive Care Med* 2010; 36: 1695–1702.

TREATMENT FOR HLH

As HLH is uncommon and serious, treatment is usually coordinated by a specialist centre experienced in treating rare immune disorders. It is also important to start therapy as soon as possible because HLH is an emergency scenario, so treatment often starts before final confirmation of the genetic diagnosis of the disease.

The priority of treatment is to damp down (suppress) the immune system to reduce the over-reaction and lessen the risk of tissue damage. Treatment is individualised to minimise the risk of any adverse effects. If HLH was triggered by an infectious agent, antimicrobial therapy may be given, which usually puts the condition into remission but the risk of relapse remains so the underlying HLH needs to be treated.

Treatments for HLH depend on its aetiology. It can include aggressive courses of immunosuppressants and anti-inflammatory agents, such as glucocorticosteroids. Initial therapy usually consists of the chemotherapy agent etoposide and the corticosteroid dexamethasone. The immunosuppressant cyclosporine can also be added to the initial treatment. If patients have EBV-related HLH, the monoclonal antibody rituximab may be used. Other agents used in the treatment of HLH include antithymocyte globulin, a T-cell depleting polyclonal antibody infusion, alemtuzumab, a lymphocyte depleting monoclonal antibody, and emapalumab, a monoclonal antibody that binds and neutralises interferon- γ . Anti-JAKs have been attempted in some cases. Regimens that include combinations of these and other drugs can diminish and slow the effects of the disease, but relapse is to be expected in patients who have primary HLH. Antibiotics, antiviral drugs and immunoglobulin replacement therapy are often administered to combat opportunistic infections.

A hematopoietic stem cell transplant (HSCT; bone marrow transplant) is the only therapy with the possibility of permanently restoring normal immune function, and hence is curative for primary HLH. Haematopoietic stem cells (HSC) from a suitable healthy donor with a good human leucocyte antigen (HLA) match are administered to replace the HSC of the recipient that will ultimately produce normal immune cells (i.e. T, B and NK cells). The ideal donor for an infant with HLH is a perfect HLA-type matched normal sibling. In the absence of an HLA identical sibling, either an HLA-matched unrelated donor (either cord blood or bone marrow) or half-matched related donor (usually one of the parents) is used. The earlier a transplant can be done, the better its chances of success.

Resolved secondary HLH does not require continuation of the therapy regimen once remission is achieved and the trigger is cured, unless disease reactivation occurs after completion of the initial therapy or unless patients are undergoing HSCT.

Patients should be continually monitored for evidence of infection because of their immunosuppressed state. Clinicians should be aware of the possibility of underlying malignancy.

LIVING WITH HLH

The outlook for children with HLH has improved, owing to better recognition of the condition and better diagnostic tests so that treatment can start as quickly as possible. New types of medicine are also being developed to treat HLH. Treatment is intensive and has side effects but many of these can be managed. HSCT remains the only cure for primary HLH but in many cases this means that children can lead a normal life after transplantation.

In the inherited forms of HLH, genetic counselling for the family is important. Prenatal diagnosis is available for future pregnancies, provided that the faulty gene can be identified.



This booklet has been produced by the International Patient Organisation for Primary Immunodeficiencies (IPOPI).

Other booklets are available in this series.

For further information and details of PID patient organisations in 63 countries worldwide please visit www.ipopi.org

www.idfa.org.au

1800 100 198

info@idfa.org.au

PO Box 742, Wollongong NSW 2520

